

# Medial Plica Syndrome of the Knee: Diagnosis with Dynamic Sonography<sup>1</sup>

Łukasz Paczesny, MD  
Jacek Kruczyński, MD, PhD

**Purpose:** To perform a feasibility study of dynamic sonography for the diagnosis of medial plica syndrome of the knee.

**Materials and Methods:** The study design was approved by the university bioethics board, and all the participants gave informed consent. Inclusion criteria were a palpable medial band, history of painful aching, and giving way or locking, which limited the subject's activity for at least 6 months. Exclusion criteria were a history of trauma with hemarthrosis, previous knee surgery, and arthrosis detectable on radiographs. A prospective evaluation in 88 subjects (56 female subjects, 32 male subjects; mean age, 20 years; range, 7–47 years) who were suspected of having a medial plica and 91 knees was performed. Three sonographic criteria were assessed during patellar movement by using a 12-MHz 38-mm linear transducer: (a) continuous echo sliding over the medial femoral condyle during medial and lateral movement of the patella, (b) entry of the echo under the patella during medial movement of the patella, and (c) pain or discomfort during dynamic sonography. Arthroscopy was the reference standard. An asymptomatic control group consisting of 32 volunteers (mean age, 28 years; range, 10–52 years) and 60 knees was also assessed.

**Results:** Arthroscopy revealed 68 plicae with pathologic findings, 61 of which met all three sonographic criteria. Medial plicae with pathologic findings were absent in 23 knees; 19 plicae were correctly diagnosed by using sonography. Diagnostic accuracy was 88%, sensitivity was 90%, and specificity was 83%. In the asymptomatic control group, there were 37 knees without a plica echo, 16 knees with a plica echo that met one criterion, and seven knees that met two criteria.

**Conclusion:** Dynamic sonography allows detection of abnormalities of medial plicae in the knee, with good sensitivity and specificity.

© RSNA, 2009

Supplemental material: <http://radiology.rsnaajnl.org/cgi/content/full/2512081652/DC1>

<sup>1</sup> From the Department of Orthopaedics for Adults and Children, Provincial Children's Hospital, Konstytucji 3 Maja 42, 87-100 Toruń, Poland (Ł.P.); and Department of Orthopaedics and Traumatology, College of Medicine, Nicolaus Copernicus University of Toruń, Bydgoszcz, Poland (J.K.). Received September 16, 2008; revision requested October 8; final revision received October 28; accepted November 10; final version accepted November 14. **Address correspondence to** Ł.P. (e-mail: [paczesny@neostrada.pl](mailto:paczesny@neostrada.pl)).

The role of medial plicae in disorders of the patellofemoral joint has been previously discussed (1–6), but many controversies on the importance of this remnant of embryological development in pathologic findings of the knee remain. In 1993, Johnson et al (7) proved the efficiency of arthroscopic resection of the plica in the treatment of plica syndrome. Unfortunately, the signs of this syndrome overlap with signs of other pathologic findings of the knee. Common clinical symptoms such as aching, giving way, a dull sensation along the medial patellar border, or joint locking are not specific and can lead to misdiagnosis. Magnetic resonance (MR) imaging has proved useful in detection of plicae (8–10) but has some disadvantages. With static MR imaging, visualization of the presence of a medial plica is possible but the dynamic behavior of the medial plica cannot be examined. Other imaging techniques, including classic arthrography or CT arthrography, are invasive.

In 1986, Derks et al (11) described the use of sonography for the diagnosis of medial plica syndrome and verified the accuracy of this method by using arthroscopy. The sensitivity of their method was 92% and the specificity was 73%. Sonography of the knee is a well-accepted diagnostic tool in orthopedics and sports medicine (12). It is useful in the assessment of meniscal lesions (13,14) and in the evaluation of anterior cruciate ligament rupture (15,16). Dynamic sonography of the knee allows tissue movement during examination and therefore relies not only on different tissue echogenicity but also on tissue adhesion in the dynamic state (17,18). Dynamic sonography, together with sonopalpation (tissue recognition under transducer pressure and pain perception when passing a transducer over the affected part), allows more accurate diagnosis of meniscal tears or ligament lesions (19,20). The aim of our study was to perform a feasibility

study of dynamic sonography for the diagnosis of medial plica syndrome of the knee.

### Materials and Methods

The study was approved by the Bioethics Board of Nicolaus Copernicus University of Toruń, Bydgoszcz, Poland. A prospective evaluation in 88 subjects (91 knees, three bilateral cases) who were suspected of having a medial plica was carried out. All the participants gave informed consent.

### Symptomatic Subject Population

Inclusion criteria were a palpable medial band and history of aching, giving way, or locking that limited the subject's normal activity. Only subjects with a history of approximately 6 months unsuccessful conservative treatment were qualified for the study. The exclusion criteria were past surgery in the involved knee, a history of trauma resulting in hemarthrosis or signs of arthrosis on anteroposterior standard radiographs. Between January 2005 and December 2007, we encountered 104 subjects (three with bilateral pathologic findings) with symptoms that met our inclusion criteria. Eight of the subjects were excluded because the onset of symptoms was connected with previous trauma that resulted in hemarthrosis. Another three had had previous surgery in the involved knee and were also excluded. The remaining 93 participants (96 knees) were enrolled and were first examined by using dynamic sonography. After a mean period of 6 months on the waiting list (range, 3–9 months), they were admitted to hospital and were examined by an orthopedic surgeon. On this occasion, five of the participants reported a subjective improvement in their condition and they were excluded from the survey. The remaining 88 subjects underwent arthroscopic surgery.

The group consisted of 56 female and 32 male subjects (three male subjects with bilateral pathologic findings), with a mean age of 20 years and an age range of 7–47 years. For the female subgroup, the mean age was 20 years, with an age range of 13–39 years. For the male subgroup, the mean age was 21 years, with an age range of 7–47 years. The accuracy of the preoperative dynamic sonographic test was blindly determined by using arthroscopy.

### Sonographic Evaluation

An examination of the knee was conducted with the use of a 12-MHz 38-mm linear transducer (HDI 4000 System; Philips Medical Systems, Andover, Mass). The examination was performed by a physician (Ł.P., with 7 years of experience in more than 2000 sonographic examinations of the knee performed with use of high-frequency transducers [ $\geq 10$  MHz]) who was not involved in the subsequent surgery. The physician was blinded to the subject's MR imaging results if there were any. First, a standard sonographic examination of the joint was performed, according to the methodology described by Grobbelaar and Bouffard (21). During this standard sonographic examination, fluid in the upper recess was identified by using transducer ballottement (22). Next, the dynamic medial plica test was performed. The subject was asked to rest in the supine position, to fully extend the knee, and to relax the quadriceps muscle. The transducer was placed in a transverse position over the anteromedial aspect of the joint (Fig 1a), allowing for visualization of the medial

### Advance in Knowledge

- This article describes a newer method of detection of medial plica syndrome by using dynamic sonography.

### Implication for Patient Care

- The use of dynamic sonography facilitates detection of plicae, which interfere with the patellofemoral joint.

### Published online before print

10.1148/radiol.2512081652

Radiology 2009; 251:439–446

### Author contributions:

Guarantor of integrity of entire study, Ł.P.; study concepts/study design or data acquisition or data analysis/interpretation, Ł.P., J.K.; manuscript drafting or manuscript revision for important intellectual content, Ł.P., J.K.; manuscript final version approval, Ł.P., J.K.; literature research, Ł.P., J.K.; clinical studies, Ł.P., J.K.; statistical analysis, Ł.P., J.K.; and manuscript editing, Ł.P., J.K.

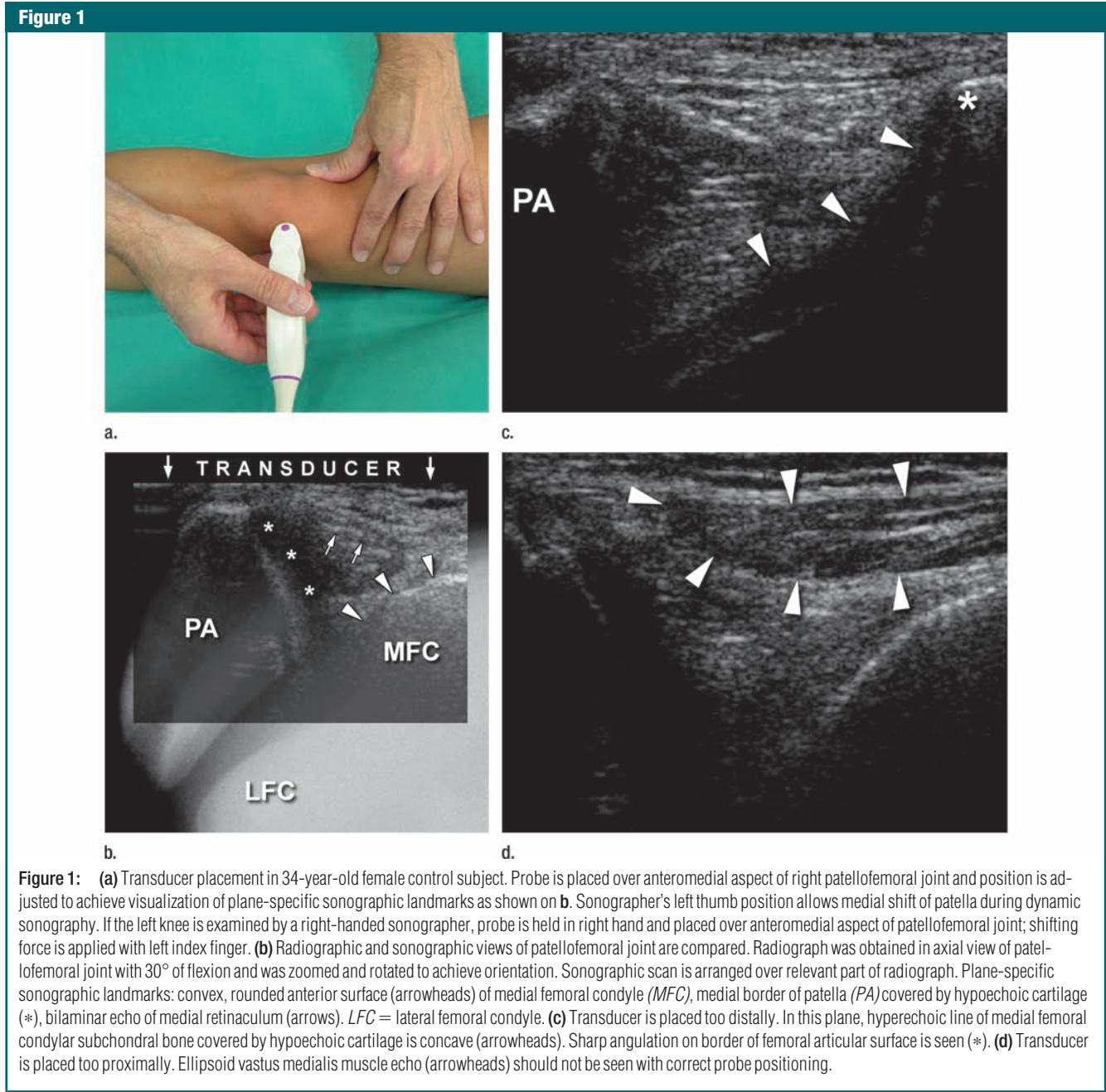Authors stated no financial relationship to disclose.

border of the patella, the patellar cartilage, and the convex border of the medial femoral condyle.

Repeatable placement of the transducer was determined by using three, plane-specific sonographic landmarks (Fig 1b): (a) the convex, rounded anterior surface of the medial femoral condyle; (b) the medial border of the patella covered by a hypoechoic cartilage echo;

and (c) a normal, bilaminar echo (21) of the medial retinaculum. If the transducer was placed too distally toward the subject's foot, the femoral condyle echo became concave, irregular, and the cartilage of the patella was difficult to identify (Fig 1c). If the transducer was placed too proximally, then the vastus medialis muscle echo appeared over the medial femoral condyle (Fig 1d). After

ensuring that the probe was correctly positioned, a static assessment of tissues around the medial border of the patella was performed (Fig 2). In this projection, the presence of a medial plica can be defined as a continuous, bandlike echo located directly over the anterior surface of the medial femoral condyle. It should be differentiated from another anatomic structure in



this region, namely the alar fold, which is a synovial fold that appears if the medial retinaculum is relaxed (6). The alar fold echo is triangular, is hyperechoic compared with the echo of a plica, and is localized directly under the medial retinaculum echo (Fig E1 [<http://radiology.rsna.org/cgi/content/full/2512081652/DC1>]). The static plica echo search was followed by a dynamic test. The patella was pressed in a medial direction to achieve approximately 1 cm of medial shift. The shifting force was then removed, and the patella returned to its normal position. The pressure put on the transducer to assess pain or discomfort when moving the patella did not exceed the force used during a normal sonographic examination.

The features noted during the dynamic test included the following: Criterion 1—The presence of a continuous echo sliding over the medial femoral condyle during medial and lateral movement of the patella. This presence confirms the presence of a medial plica but does not determine whether it is a pathologic finding. Criterion 2—The entry of this echo under the patella during medial movement of the pa-

tella. This entry of the echo helps depict plica contact with the patellar cartilage, the so-called internal derangement caused by plica (23). Criterion 3—Pain or discomfort during dynamic sonography.

The test results were regarded as positive if all three criteria were met. If a plica echo could not be detected sonographically (criterion 1 missed) (Fig E2, Movie 3 [<http://radiology.rsna.org/cgi/content/full/2512081652/DC1>]) or if it ended over the medial femoral condyle and did not contact the patellar cartilage during patella movement (Fig E1, Movie 2 [<http://radiology.rsna.org/cgi/content/full/2512081652/DC1>]), then the dynamic test outcome was regarded as negative. If manual manipulation during the test did not cause pain or discomfort (criterion 3 missed), then the test results were also regarded as negative.

Tissue movement on the sonogram was registered on the hard disk of the sonographic machine. Clips were exported to an uncompressed Audio Video Interleave format and compressed to Moving Picture Experts Group 4 format by using software (AVS Video Tools Software, version 5.6.1.705; Online Media Technologies, London, England).

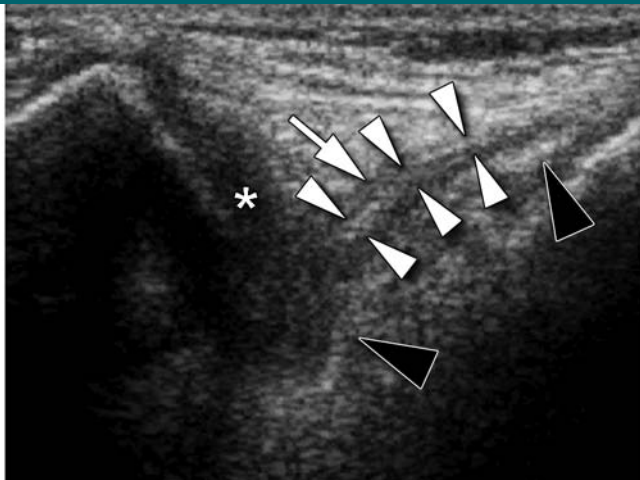
### Dynamic Sonography in the Asymptomatic Control Group

A dynamic sonographic test was performed in 60 asymptomatic knees. The group consisted of 32 healthy volunteers (19 female and 13 male subjects) aged 10–52 years, with a mean age of 28 years. For the female subgroup, the mean age was 29 years, with an age range of 12–43 years. For the male subgroup, the mean age was 26 years, with an age range of 10–52 years. Four control subjects had a history of transient knee pain, and these joints were excluded from the examination. Instead, a unilateral examination of the knee without a history of pain was performed in these cases. The same diagnostic procedure for the dynamic sonographic test was performed.

### Arthroscopic Evaluation

Arthroscopy was performed in the orthopedic department by an orthopedic surgeon (J.K., who specialized in arthroscopic procedures for 25 years and performed more than 5000 arthroscopic procedures of the knee). The operator was blinded to the sonographic results and based his diagnosis solely on the clinical history, the results of the participant's evaluation, and findings at arthroscopy. A standard 30° 5.6-mm arthroscope (Karl Storz, Tuttlingen, Germany) was introduced through the anterolateral portal, and a standard arthroscopic examination was performed with the use of an arthroscopic probe (Acuflex Microsurgical, Mansfield, Mass). Video documentation of the procedure was registered on a video tape recorder (SVO-9500MD; Sony Medical Systems, Park Ridge, NJ). Plica position and possible impingement (plica interfering between the patella and the medial femoral condyle) were observed during flexion and extension. The extent and tension of the structures in the antero-medial compartment were determined by means of the arthroscopic probe. High fluid pressure (0.9% saline) pushed the synovial folds back to the joint capsule, and the fluid was then evacuated to allow the medial plica to return to its normal position. The best visualization was possible when the arthroscope

**Figure 2**



**Figure 2:** Sonogram of symptomatic right knee in 15-year-old female subject. Medial plica echo was defined as hyperechoic longitudinal zone (white arrowheads) sliding over anterior surface of medial femoral condyle (black arrowheads) toward hypoechoic patellar cartilage echo (\*) during dynamic examination. Thin hypoechoic border (arrow) of plica echo was seen. Dynamic sonographic test is shown in Movie 1 (<http://radiology.rsna.org/cgi/content/full/2512081652/DC1>).

was placed near the inferior pole of the patella and the fluid was then gradually evacuated. If the plica interfered with the patella and medial femoral condyle, it was widely excised with the use of a shaver (TPS 12K; Stryker Endoscopy, San Jose, Calif). If a diagnosis other than plica syndrome was established, the appropriate procedure was performed.

**Statistical Analysis**

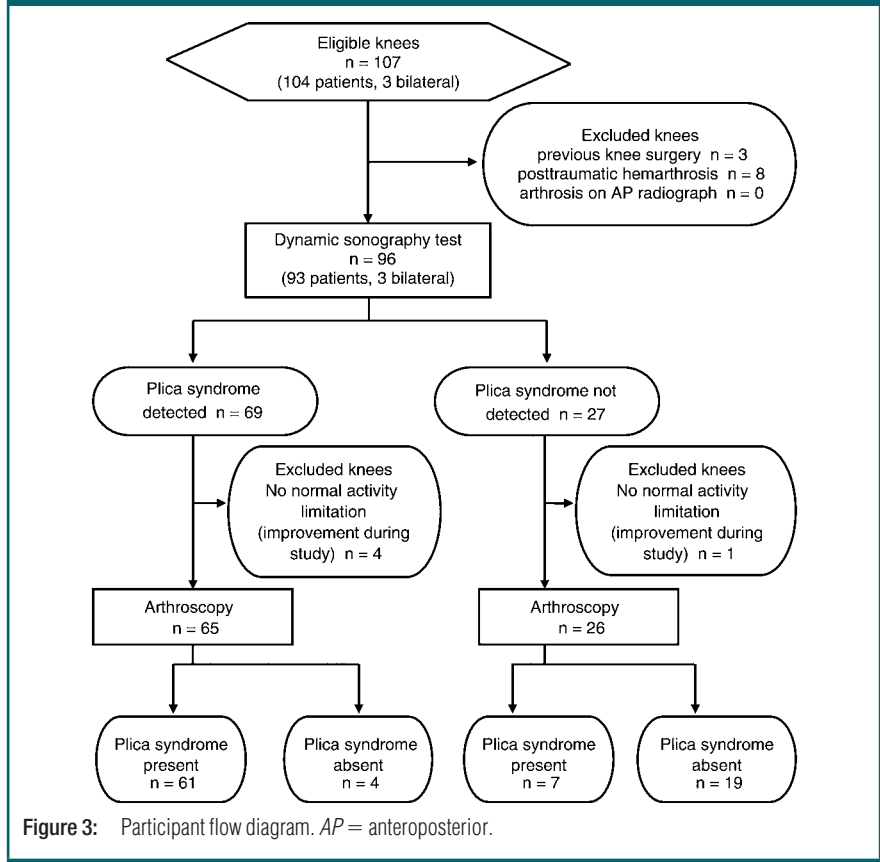
Data were correlated and analyzed with statistical software (BioStat, version 2007; AnalystSoft, Vancouver, British Columbia, Canada). Accuracy, sensitivity, specificity (with 95% confidence intervals), as well as positive and negative predictive values were computed.

**Results**

**Clinical Data**

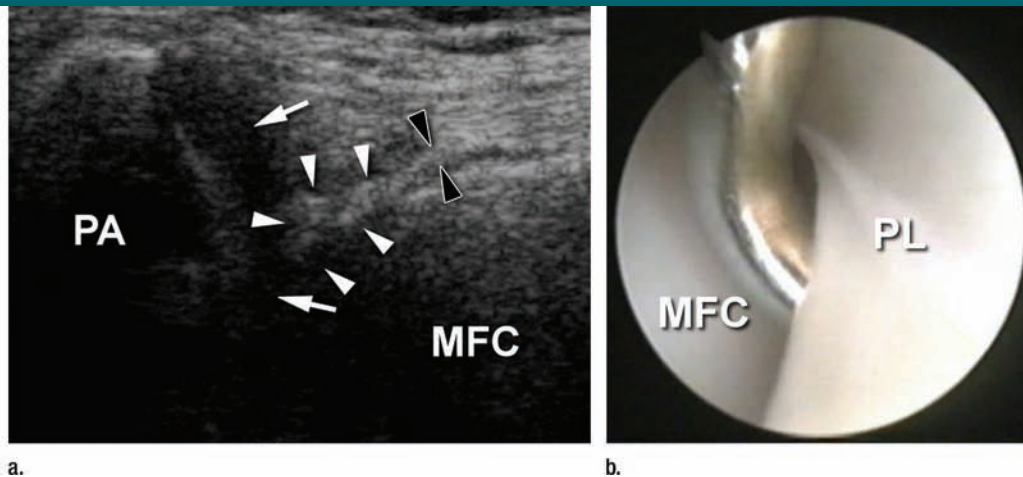
Inclusion criteria, exclusion criteria, and outcome are shown in Figure 3. Arthroscopy revealed 68 medial plicae with pathologic findings; 61 of them were correctly diagnosed by using dynamic sonography (Figs 4, 5; Fig E3, Movies 8, 9

**Figure 3**



**Figure 3:** Participant flow diagram. AP = anteroposterior.

**Figure 4**



**Figure 4:** Sonogram in a 15-year-old female subject with history of pain, occasional knee locking, and severe limitation of sporting activity for 2 years previous to test. Triangular medial plica echo (white arrowheads) surrounded by hypoechoic border contacting a hypoechoic patellar cartilage (arrows). Medial part of plica (black arrowheads) extends over medial femoral condyle (MFC). PA = patella. Dynamic sonographic test is shown in Movie 4 (<http://radiology.rsna.org/cgi/content/full/2512081652/DC1>). (b) Medial plica (PL) bent over arthroscopic probe. Arthroscopic procedure is shown in Movie 5 (<http://radiology.rsna.org/cgi/content/full/2512081652/DC1>), which demonstrates plica resection following diagnostic procedure.

[<http://radiology.rsnajnl.org/cgi/content/full/2512081652/DC1>].

All three bilateral cases were found in men. Of the seven false-negative results (Table 1), there were four cases in which heterogeneous changes in the medial meniscus found during sonography were initially interpreted as lesions of the meniscus. A plica echo was found in these cases, but only criterion 1 was met. Two other false-negative results occurred when general synovial hypertrophy was seen in the upper recess during sonography, but again only criterion 1 was met in the dynamic sonographic test. In one case only, high localization of the patella (patella alta) was seen at sonography, but none of the three criteria were met; during surgery, a medial plica was found in the knee and excised.

The dynamic sonographic test results for plicae with pathologic findings were negative in 23 knees, and in 19 of these knees, the diagnosis was correct. In one of the four false-positive cases (Table 2), there was a large cartilage defect of the medial femoral condyle (osteochondritis dissecans), which was seen at sonography but was classified as only an International Cartilage Repair Society grade 2 lesion. Criterion 3 was

probably met because of the painful cartilage lesion localized over the medial femoral condyle. In this case, an effusion of the knee was observed. One subject had no history of hemarthrosis, and in this instance, misdiagnosis occurred. Here, a plica that met all three criteria was seen by using sonography, but surgery revealed instead anterior cruciate ligament rupture and minor tears of both menisci. Effusion with pathologic findings in the knee also was present, but this was present in only two cases. In the other false-positive case, a medial plica that met all three criteria was established as the main diagnostic feature in the knee of an obese 16-year-old female subject, while overload meniscal tears of both menisci were found during surgery. In the fourth false-positive case, a plica that met all three criteria was indicated by using sonography, but at surgery, lateralization of the patella was found; synovial plica resection was not performed. The diagnostic accuracy of the sonographic method was 88%, with a sensitivity of 90% and a specificity of 83% (Table 3).

#### Asymptomatic Control Group

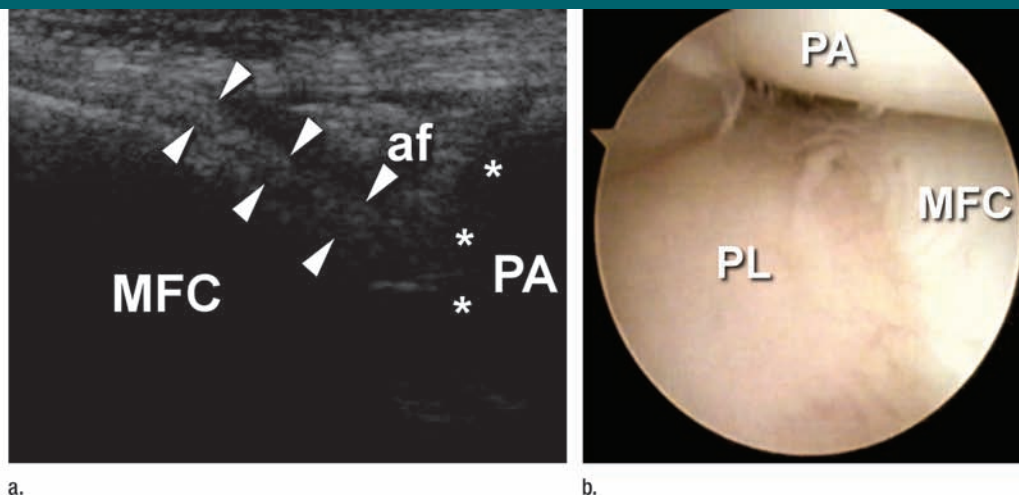
In the asymptomatic control group consisting of 60 knees, we found seven

knees that met criteria 1 and 2 but not criterion 3. In other words, the plica echo appearance in these cases was an indication of a pathologic finding, but while the plica interfered with the cartilage of the patella there was no pain or discomfort during the examination. Another 16 knees of the control group revealed plica echoes that met criterion 1, but the other two criteria were missing. In the remaining 37 joints in the control group, the plica echo was absent.

#### Discussion

There have been various studies on the diagnosis of the plica syndrome, but we could find only one on the application of sonography in the diagnosis of a medial plica. In 1986, Derks et al (11) described the use of a 7.5-MHz sector transducer in medial shelf detection later verified by using arthroscopy, but they did not examine the patellofemoral joint during movement of the patella. The sensitivity of their method was 92% and the specificity was 73%. In our study, the presence of the plica was determined during a dynamic examination: The patella was moved, and the behavior of the plica echo was judged by using specific criteria. In 2007, Shetty et al (24) reported the high sensitivity

Figure 5



**Figure 5:** (a) Sonogram of left knee in 16-year-old male subject with history of aching, giving way, and occasional locking of both knees. Medial plica echo (arrowheads) is in contact with patellar cartilage (\*). *af* = Alar fold, *MFC* = medial femoral condyle, *PA* = patella. Dynamic sonographic test is shown in Movie 6 (<http://radiology.rsnajnl.org/cgi/content/full/2512081652/DC1>). (b) Medial plica (*PL*) was found during arthroscopy. Arthroscopic procedure is shown in Movie 7 (<http://radiology.rsnajnl.org/cgi/content/full/2512081652/DC1>).

and specificity of a clinical test for the diagnosis of the medial plica syndrome. The reliability of this method of clinical examination needs future assessment. The dynamic sonographic technique presented in our study may help to avoid more costly tests or misdiagnoses.

Our study had limitations. The sonologist was involved in patient care in both the orthopedic department and the outpatient clinic and, thus, was not blinded to patient symptoms or the control population, which may have led to observer bias. We had only a single physician perform the study, and, thus, interobserver variability of our method was not evaluated. Because of the long waiting lists in our country's health care system, our patients had had to wait about 6 months for surgery. This resulted in the spontaneous relief of symptoms in five patients. Our third criterion of pain was, thus, patient and time dependent. Sonologists who perform dynamic sonography should realize that pain in patients with the plica syndrome can be intermittent, and this factor could cause false-negative results to occur. Finally, we did not make any plica measurements because we believe that plica thickness is of secondary importance and that the amount of medial femoral condyle coverage and its interaction with the patella are more important in clinical practice. Boles et al (25), in their study with MR imaging, found no correlation between plica thickness and its arthroscopic features.

An important finding in our study was that, in our group of relatively young subjects, a plica as an isolated lesion was never accompanied by joint effusion. The problem for the surgeon in the diagnosis of isolated medial plica syndrome is its poorly expressed objective symptoms. These symptoms are, therefore, difficult to verify by means of clinical examination, but they substantially limit the patient's activity. We were unable to find a similar observation in regard to a lack of effusion in the literature, but Boles et al (25) noted that a smaller effusion makes visualization of the medial plica at MR imaging less apparent. Therefore, a plica is bet-

**Table 1****False-Negative Outcomes of Dynamic Sonographic Test for Diagnosis of Medial Plicae with Pathologic Findings**

Patient Sex/Age (y)	Side	Sonographic Findings	Arthroscopic Findings
F/16	Right	Medial meniscus lesion	Plica syndrome
M/15	Left	Medial meniscus lesion	Plica syndrome
M/32	Left	Medial meniscus lesion	Plica syndrome
M/18	Left	Medial meniscus lesion	Plica syndrome
F/14	Right	General synovial hypertrophy	Plica syndrome, ICRS grade 1 cartilage defect of patella
F/15	Left	General synovial hypertrophy	Plica syndrome, patella lateralization
F/18	Left	Patella alta	Plica syndrome, ICRS grade 1 cartilage defect of patella

Note.—ICRS = International Cartilage Repair Society.

**Table 2****False-Positive Outcomes of Dynamic Sonographic Test for Medial Plicae with Pathologic Findings**

Patient Sex/Age (y)	Side	Sonographic Findings	Arthroscopic Findings
F/17	Right	Plica syndrome, ICRS grade 2 cartilage defect of medial femoral condyle, effusion fluid	ICRS grade 4 cartilage defect of medial femoral condyle, corpus liberum, ICRS grade 1 cartilage defect of patella
F/16	Right	Plica syndrome, ICRS grade 2 cartilage defect of medial femoral condyle	Lateral and medial meniscus lesions, ICRS grade 3 cartilage defect of medial femoral condyle
F/20	Right	Plica syndrome	Patella lateralization, ICRS grade 2 cartilage defect of patella
F/32	Left	Plica syndrome, effusion fluid	Anterior cruciate ligament lesion, lateral and medial meniscus lesions

Note.—ICRS = International Cartilage Repair Society.

ter visualized by using MR imaging when there is effusion in the joint, but in existing studies, a plica frequently coexisted with other pathologic findings in the knee (eg, meniscal lesions or severe lesions of the cartilage in older patients) (8,10,23). Most of these effusion-causing pathologic findings are well diagnosed by using MR imaging. For this reason, we recommend MR imaging examination as a first-choice imaging modality when the results of clinical examination suggest a medial plica and coexisting effusion. During the diagnostic process, it is important to differentiate between those patients with symptoms of the medial plica syndrome who require arthroscopic surgery from those who can be treated conservatively (26).

**Table 3****Diagnostic Performance of Dynamic Sonographic Test for Detection of Medial Plicae with Pathologic Findings**

Statistic	Value (%)	95% Confidence Interval (%)
Accuracy	88	...
Sensitivity	90	82.5, 96.9
Specificity	83	67.1, 98.1
Positive predictive value	94	...
Negative predictive value	73	...

To simply draw the conclusion from the findings of static MR imaging that there is a plica in the anteromedial compart-

ment is not sufficient. The important question in clinical practice is this: Does the medial plica interfere dynamically with the patellofemoral joint? If the answer is yes, then arthroscopic resection of the plica should relieve the symptoms. If the answer is no, then it is possible that the anterior knee pain is connected with homeostatic disorders of the patellofemoral joint (27) rather than mechanical internal derangement of the plica. The dynamic sonographic technique described in this article provides a high level of sensitivity and specificity in the diagnosis of the nature of medial plica interaction with the patella and medial femoral condyle. Dynamic sonography, therefore, can help the surgeon to make the critical decision of whether to perform surgery or not.

**Acknowledgments:** We thank Geoffrey Shaw, DDS, FDSRCS, Department of Biomaterials and Experimental Dentistry, University of Medical Sciences, Poznań, Poland, for his linguistic correction and Przemysław Czystkowski, MD, PhD, Department of Radiology and Diagnostic Imaging, City Hospital, Toruń, Poland, for his helpful suggestions.

## References

- Dandy DJ. Arthroscopy in the treatment of young patients with anterior knee pain. *Orthop Clin North Am* 1986;17(2):221-229.
- Denti M, Monteleone M, Berardi A, Arosio A. Medial patellar synovial plica syndrome: the influence of associated pathology on long-term results. *Chir Organi Mov* 1994;79(3):273-277.
- Dorchak JD, Barrack RL, Kneisl JS, Alexander AH. Arthroscopic treatment of symptomatic synovial plica of the knee: long-term followup. *Am J Sports Med* 1991;19(5):503-507.
- Calpur OU, Tan L, Gurbuz H, Moralar U, Copuroglu C, Ozcan M. Arthroscopic mediopatellar plicaectomy and lateral retinacular release in mechanical patellofemoral disorders. *Knee Surg Sports Traumatol Arthrosc* 2002;10(3):177-183.
- Flanagan JP, Trakru S, Meyer M, Mullaji AB, Krappel F. Arthroscopic excision of symptomatic medial plica: a study of 118 knees with 1-4 year follow-up. *Acta Orthop Scand* 1994;65(4):408-411.
- Boles CA, Martin DF. Synovial plicae in the knee. *AJR Am J Roentgenol* 2001;177(1):221-227.
- Johnson DP, Eastwood DM, Witherow PJ. Symptomatic synovial plicae of the knee. *J Bone Joint Surg Am* 1993;75(10):1485-1496.
- García-Valtuille R, Abascal F, Cerezal L, et al. Anatomy and MR imaging appearances of synovial plicae of the knee. *RadioGraphics* 2002;22(4):775-784.
- Kruczyński J, Ziemiański A. Medial patellar plica of the knee in MR examination and arthroscopy [in Polish]. *Chir Narządów Ruchu Ortop Pol* 1995;60(4):313-317.
- Nakanishi K, Inoue M, Ishida T, et al. MR evaluation of mediopatellar plica. *Acta Radiol* 1996;37(4):567-571.
- Derks WH, de Hooge P, van Linge B. Ultrasonographic detection of the patellar plica in the knee. *J Clin Ultrasound* 1986;14(5):355-360.
- Friedman L, Finlay K, Jurriaans E. Ultrasound of the knee. *Skeletal Radiol* 2001;30(7):361-377.
- Casser HR, Sohn C, Kiekenbeck A. Current evaluation of sonography of the meniscus: results of a comparative study of sonographic and arthroscopic findings. *Arch Orthop Trauma Surg* 1990;109(3):150-154.
- Petersen LJ, Rasmussen OS. Ultrasonography as a diagnostic method in suspected meniscal lesion of the knee: a prospective single blind study of 52 patients [in Danish]. *Ugeskr Laeger* 1999;161(41):5679-5682.
- Khan Z, Faruqi Z, Ogyunbiyi O, Rosset G, Iqbal J. Ultrasound assessment of internal derangement of the knee. *Acta Orthop Belg* 2006;72(1):72-76.
- Ptasznik R, Feller J, Bartlett J, Fitt G, Mitchell A, Hennessy O. The value of sonography in the diagnosis of traumatic rupture of the anterior cruciate ligament of the knee. *AJR Am J Roentgenol* 1995;164(6):1461-1463.
- Khoury V, Cardinal E, Bureau NJ. Musculoskeletal sonography: a dynamic tool for usual and unusual disorders. *AJR Am J Roentgenol* 2007;188(1):W63-W73.
- Segal A, Miller TT, Krauss ES. Fabellar snapping as a cause of knee pain after total knee replacement: assessment using dynamic sonography. *AJR Am J Roentgenol* 2004;183(2):352-354.
- Füsting M, Casser HR. Dynamic examination technique in meniscus sonography [in German]. *Sportverletz Sportschaden* 1991;5(1):27-36.
- Friedl W, Glaser F. Dynamic sonography in the diagnosis of ligament and meniscal injuries of the knee. *Arch Orthop Trauma Surg* 1991;110(3):132-138.
- Grobelaar N, Bouffard JA. Sonography of the knee, a pictorial review. *Semin Ultrasound CT MR* 2000;21(3):231-274.
- Karim Z, Wakefield RJ, Quinn M, et al. Validation and reproducibility of ultrasonography in the detection of synovitis in the knee: a comparison with arthroscopy and clinical examination. *Arthritis Rheum* 2004;50(2):387-394.
- Munzinger U, Ruckstuhl J, Gschwend N. Internal derangement of the knee joint due to pathologic synovial folds: the mediopatellar plica syndrome. *Clin Orthop Relat Res* 1981;155:59-64.
- Shetty VD, Vowler SL, Krishnamurthy S, Halliday AE. Clinical diagnosis of medial plica syndrome of the knee: a prospective study. *J Knee Surg* 2007;20(4):277-280.
- Boles CA, Butler J, Lee JA, Reedy ML, Martin DF. Magnetic resonance characteristics of medial plica of the knee: correlation with arthroscopic resection. *J Comput Assist Tomogr* 2004;28(3):397-401.
- Fulkerson JP. Diagnosis and treatment of patients with patellofemoral pain. *Am J Sports Med* 2002;30(3):447-456.
- Dye SF. The pathophysiology of patellofemoral pain: a tissue homeostasis perspective. *Clin Orthop Relat Res* 2005;436:100-110.